



# Orofacial Granulomatosis and Crohn's Disease: A Case Series

Siri A. Urquhart, MD<sup>1</sup>, Grace Y. Kim, MD<sup>2</sup>, Katelyn R. Anderson, MD<sup>2</sup>, and Victor G. Chedid, MD, MS<sup>1</sup>

<sup>1</sup>Division of Gastroenterology and Hepatology, Mayo Clinic, Rochester, MN

<sup>2</sup>Department of Dermatology, Mayo Clinic, Rochester, MN

## ABSTRACT

Orofacial granulomatosis (OFG) is a rare syndrome that can occur in association with Crohn's disease (CD). The electronic medical record was searched for "OFG" and "CD." A total of 297 patients were identified, and relevant data were abstracted. Five patients met inclusion criteria. Most (80%) had ileocolonic CD with nonstricturing/nonpenetrating phenotype. The most common treatments included intralesional corticosteroids (4 patients), oral corticosteroids (3 patients), and anti-TNF agents, specifically infliximab (3 patients). Intralesional corticosteroid administration was followed by partial response in 3 patients, but recurrences were common following initial injection. One patient had no response to topical or oral corticosteroids, antihistamines, or oral antibiotics, but partial response to intralesional corticosteroids and infliximab. None of the patients had complete response to any therapies directed at this condition. OFG may be characterized by partial response, often requiring long-term therapy. Additional investigations into novel treatments may improve future clinical outcomes.

**KEYWORDS:** crohn's disease; orofacial granulomatosis; granulomatous cheilitis

## INTRODUCTION

Inflammatory bowel disease (IBD), specifically Crohn's disease (CD), is a systemic condition that manifests not only in the gastrointestinal (GI) tract but also in extraintestinal organs in many patients. The quality of life for patients with IBD can be substantially affected by these extraintestinal manifestations (EIMs), which can occur in up to 24% of patients with IBD before the onset of intestinal symptoms.<sup>1</sup> Cutaneous EIMs have been reported in 5%–15% of patients with IBD.<sup>2</sup> It may be disputed whether oral lesions represent an EIM or are rather a manifestation of IBD. The prevalence of oral lesions is reported in a range from 5% to 50%.<sup>3–5</sup> Oral lesions are reported to be more common in patients with CD and more prevalent in children.<sup>1</sup>

Orofacial granulomatosis (OFG) is an uncommon condition characterized by the histologic finding of noncaseating granulomas within the face and oral mucosa on tissue biopsy, resulting in persistent swelling.<sup>6–8</sup> OFG is found in less than 1% of patients with CD, and biopsy is the most effective means of establishing the diagnosis.<sup>8,9</sup> Some may consider OFG a distinct condition without a systemic granulomatous disorder, while others consider this to be a broader diagnosis encompassing isolated OFG and a possible manifestation of CD or sarcoidosis. OFG often follows a chronic and disfiguring course, making it exceptionally difficult to manage and ultimately affecting the quality of life in affected patients.<sup>8,9</sup>

OFG has been described in the literature as an independent entity and a subtype of CD. In a systematic review from Gavioli et al, OFG often presented as a distinct, independent condition, but carried a higher risk of developing CD, especially in the pediatric population.<sup>10</sup> OFG may occur before CD and those with concurrent CD may be more likely to have buccal sulcus involvement. In a systematic review from Lazzarini et al, there is a high prevalence of CD in pediatric patients with OFG, with 40.4% diagnosed with both conditions. OFG may therefore be a subtype of CD as OFG often precedes the diagnosis of CD. Perianal disease and family history of CD were significantly associated with a higher risk of CD in pediatric patients with OFG.<sup>11</sup> Patients with CD and coexistent OFG may also have a distinct phenotype characterized by a higher incidence of perianal disease, intestinal granulomas, and greater need for extensive therapy including perianal surgery and combination immunomodulatory treatments to achieve remission.<sup>12,13</sup>

OFG and CD share several pathophysiologic features, suggesting a potential relationship between these 2 conditions. One key aspect of the pathophysiologic relationship is the immune environment. Freysdottir et al described a Th1-dominant immune response in OFG tissue, similar to that observed in CD. Specifically, increased levels of CD4<sup>+</sup> T cell, interferon gamma, and other Th1 cytokines have been noted in OFG, mirroring the immunopathological features of CD.<sup>14</sup> Genetic factors also play a significant role. Variants in NOD2 gene, which are associated with CD, have been found in patients with OFG, particularly in those with concurrent intestinal disease.<sup>15</sup>

Given the rarity of this syndrome and discrepancies in the literature as to if OFG is an independent clinical entity or a subtype of CD with a distinct phenotype, we aimed to retrospectively review our institutional experience to better describe the clinical features, presentation, and outcomes of OFG in patients with CD.

## METHODS

**Patient population:** This retrospective study was approved by the Mayo Clinic Institutional Review Board. All patients were identified based on a search of *International Classification of Diseases-9/10* diagnostic codes and clinical notes search through an institutional bioinformatic tool to include diagnoses of OFG (including granulomatous cheilitis, cheilitis granulomatosa, and Melkersson-Rosenthal syndrome) and CD between January 1992 and May 2023. This was followed by manual review of individual patient charts as permitted by Minnesota Health Records Act, 144.295, which allows patients to opt out of retrospective research.

In patients with a confirmed OFG and CD diagnosis, relevant demographic and clinical outcomes were abstracted. The date of first visit for CD and/or OFG diagnosis (index) was recorded. We excluded patients without confirmed OFG or CD diagnosis on record, absence of pathology report on file confirming OFG, and absence of endoscopic procedure on file confirming CD diagnosis.

**Crohn's disease characteristics:** CD was diagnosed based on clinical diagnostic criteria as per the treating gastroenterologist and review of the medical record for the confirmation of characteristic endoscopic, radiographic, and/or histologic findings. The date of CD diagnosis was defined by the earliest pathologic confirmation at our institution. Related complications such as upper GI involvement or perianal disease and former or current tobacco use were abstracted. CD characteristics included extent of disease involvement, disease behavior, and prior medical therapies trialed for CD.

**OFG characteristics:** OFG was diagnosed based on the presence of typical clinical features including lip erythema, edema, and/or ulceration of oral mucosa in addition to histologic features consistent with the diagnosis including lymphocytic

inflammatory infiltrate with noncaseating (non-necrotizing) granulomas. The date of OFG diagnosis was defined by the earliest pathologic confirmation at our institution. Prior treatment strategies for OFG were recorded including treatment duration, patient response, and time to response.

**Statistical analysis:** Patient characteristics and clinical data were presented as mean with SD, median with range, or frequency with percentages. Descriptive statistics were used to report findings. Categorical variables were reported as a unique count and percentage of the sample.

## RESULTS

The initial data search identified 297 patients with suspected cases of OFG and CD. After manual review, 5 patients were included in the final analysis, and 292 were excluded (Figure 1).

**Crohn's disease characteristics:** Five patients met inclusion criteria (40% female), with a median age of 15 years at the time of CD diagnosis. Most (80%) had ileocolonic distribution of CD. Two (40%) had upper GI involvement, and 1 (20%) had perianal involvement. Nonstricturing/penetrating (80%) was the most common CD phenotype. OFG was diagnosed in 1 (20%) before CD, 2 (40%) concurrently with CD, and 2 (40%) after CD diagnosis. At the time of OFG diagnosis, CD was active in 2 (40%) and quiescent in 2 patients (40%).

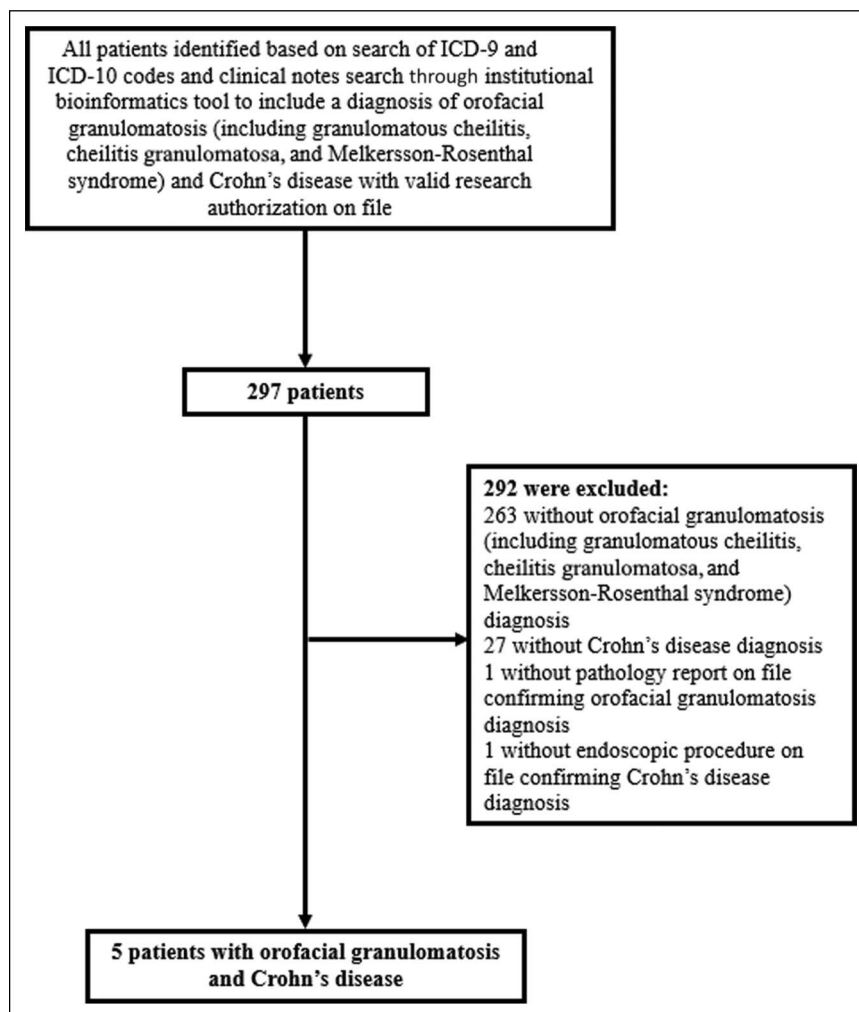
Previous treatments of CD included 5-aminosalicylate only (20%), oral corticosteroids (20%), anti-tumor necrosis factor (anti-TNF) +/- immunomodulator (60%), and ustekinumab (20%). Only one patient had prior surgical resection for CD (Table 1).

**OFG characteristics:** The median age was 14 years at the time of OFG diagnosis. OFG was confirmed histologically in all patients. The most common presenting symptom associated with OFG was lip swelling (80%) (Table 1).

The most common treatment strategies for OFG included intralesional corticosteroids (4 patients), oral corticosteroids (3 patients), and anti-TNF agents, specifically infliximab (3 patients). Although intralesional corticosteroid administration was followed by partial response in 3 patients, recurrences were common after the initial injection. One patient had no response to topical corticosteroids, oral corticosteroids, antihistamines, or oral antibiotics, but partial response to intralesional corticosteroids and infliximab. None of the patients had complete response to any therapies directed at OFG (Table 2).

## DISCUSSION

While aphthous ulcerations of the mouth are well-recognized manifestations of active disease, OFG is a rare syndrome that may occur in association with CD.<sup>7</sup> In our study, OFG associated with CD may occur before, concurrently with, or after the



**Figure 1.** Screening of patients for study inclusion. Using an institutional bioinformatics search tool, all patients were identified using a combination of *International Classification of Diseases-9/ICD-10* codes and search terms including “orofacial granulomatosis,” “granulomatous cheilitis,” “cheilitis granulomatosa,” “Melkersson-Rosenthal syndrome,” and “Crohn’s disease” who had a valid research authorization on file. A total of 292 patients were excluded.

diagnosis of CD and most often occurs in younger patients. Ileocolonic distribution of CD is a common association, in addition to the presence of upper GI involvement and perianal disease.

The treatment of OFG in patients with CD involves a combination of therapies targeting both the oral and GI manifestations of the disease. Given the shared pathophysiologic mechanisms, treatment strategies often overlap but require tailored approaches based on the severity and specific manifestations of each condition. Spontaneous remission is rare, and with lack of controlled trials, different therapeutic approaches have been used for treatment. Several drugs have been used with variable results, and there is no consensus regarding optimal treatment.<sup>16,17</sup>

First-line treatments for OFG typically include topical and systemic corticosteroids. However, these often provide only short-term relief and are not suitable for long-term

management due to potential side effects.<sup>18</sup> Intralesional corticosteroids, such as triamcinolone acetonide, have shown long-term effectiveness in reducing orofacial swelling and maintaining remission in OFG. In a study by Mignogna et al, 57.9% of patients achieve complete clinical remission with intralesional triamcinolone acetonide alone, while those partially responsive to triamcinolone acetonide achieved remission with the addition of topical pimecrolimus.<sup>19</sup> Fedele et al also reported 63.6% of patients did not experience disease recurrence after one course of triamcinolone acetonide, with mean disease-free period of 28.9 months.<sup>20</sup> However, systemic corticosteroids are generally used as a bridge to more sustainable therapies.<sup>18–21</sup>

Immunosuppressive agents such as azathioprine have shown the efficacy, particularly in patients with concurrent OFG and CD. Mentzer et al reported 59% of patients with CD, and OFG responded to azathioprine at 12 months, compared with 21% of those with OFG alone.<sup>22</sup> The use of immunomodulators in

**Table 1. Demographic and clinical characteristics of patients with Crohn's disease and orofacial granulomatosis**

Characteristic	Patients (N = 5)
Age, median (range), y	
At CD diagnosis	15 (9–26)
At OFG diagnosis	14 (9–59)
Sex, female to male ratio	2:3
CD distribution, n (%)	
Ileocolonic	4 (80.0)
Ileal	1 (20.0)
Colonic, isolated	0 (0.0)
Upper GI involvement	2 (40.0)
Perianal involvement	1 (20.0)
CD phenotype, n (%)	
Nonstricturing/penetrating	4 (80.0)
Stricturing	0 (0.0)
Penetrating	1 (20.0)
Tobacco use history, n (%)	
Current or former	0 (0.0)
Never	5 (100.0)
Timing of OFG diagnosis in relation to CD diagnosis, n (%) <sup>a</sup>	
Before CD diagnosis	1 (20.0)
Concurrently with CD diagnosis	2 (40.0)
After CD diagnosis	2 (40.0)
CD activity at the time of OFG diagnosis, n (%)	
Active	2 (40.0)
Quiescent	2 (40.0)
CD not yet diagnosed	1 (20.0)
OFG diagnosis, n (%)	
Clinically	5 (100.0)
Granulomas on histology	5 (100.0)
Clinical presentation associated with OFG, ratio to total	
Erythema	1 (20.0)
Lip edema	4 (80.0)
Ulceration of oral mucosa	1 (20.0)
Previous treatments for luminal CD, n (%)	
No medications	1 (20.0)
5-ASA only	1 (20.0)
Oral corticosteroids	1 (20.0)
Anti-TNF +/- immunomodulator <sup>b</sup>	3 (60.0)
Ustekinumab	1 (20.0)
Previous surgical resection <sup>c</sup>	1 (20.0)
Percentages were calculated on the basis of those with data available.	
5-ASA, 5-aminosalicylate; anti-TNF, anti-tumor necrosis factor; CD, Crohn's disease; GI, gastrointestinal; OFG, orofacial granulomatosis.	

a In the patient with a diagnosis of OFG before CD, duration between diagnoses was 24 months. In the 2 patients with a diagnosis of OFG after CD, duration between diagnoses was 22 months to 39 years.

b Anti-TNF agents included infliximab and adalimumab. Immunomodulator agents included methotrexate.

c One patient underwent ileal pouch-anal anastomosis 10 years after CD diagnosis.

combination with biologics is often necessary for severe or refractory diseases. Malmquist et al found 36% of patients with OFG and CD were on combination therapy at the end of a 5-year observation period, indicating a need for extensive therapy to manage these concomitant conditions.<sup>12</sup>

Biologic therapies have shown significant efficacy in managing both OFG and CD. Anti-TNF agents, such as infliximab and adalimumab, are commonly used and have been effective in inducing remission in patients with both conditions. In a multicenter case series supported by the European Crohn's and Colitis Organization, anti-TNF agents were used successfully in 9 patients with OFG associated with CD.<sup>13,23</sup> Infliximab has been reported to have a 71% short-term response rate, but a significant proportion of patients may lose response over time.<sup>24</sup> Other biologics, including vedolizumab and ustekinumab, have also been used successfully in some cases. Phillips et al noted remission was achieved in 23 of 28 patients using various biologics, including anti-TNFs, vedolizumab, and ustekinumab.<sup>13</sup> The American Gastroenterological Association recommends anti-TNF agents for treating severely active CD, which can include OFG manifestations.<sup>25</sup>

In our study, patients required similar treatment modalities in comparison with those as described in the literature. These included intralesional corticosteroids (4 patients), oral corticosteroids (3 patients), and anti-TNF agents, specifically infliximab (3 patients). Although intralesional corticosteroid administration was followed by partial response in 3 patients, recurrences were common after the initial injection. One patient had no response to topical corticosteroids, oral corticosteroids, antihistamines, or oral antibiotics, but partial response to intralesional corticosteroids and infliximab. None of the patients had complete response to any therapies directed at OFG. This may reflect inherent limitations in our study, including it being performed at a single tertiary referral center, which may result in bias, limiting generalizability. This was also a retrospective study, and as a result, there was significant reliance on documentation within the electronic medical record. However, we used a large patient database and identified all possible patients with OFG and CD at our institution.

Despite the availability of different treatment modalities, the management of OFG remains challenging. None of the patients in this series achieved complete remission, highlighting the need for ongoing management and patient counseling regarding partial responses. Future research into novel therapies is essential to improve outcomes for OFG in CD.

**Table 2. Treatments and responses in 5 patients with Crohn's disease and orofacial granulomatosis**

Treatment	No. of patients	Treatment duration, median (range), mo	Response			Time to response, median (range), mo
			NR <sup>a</sup>	PR <sup>b</sup>	CR <sup>c</sup>	
Topical tacrolimus	1	30	0	1	0	2
Topical corticosteroids	1	N/A	1	0	0	N/A
Intralesional corticosteroids	4	14 (2–21)	0	3	0	1 (27 d to 2 mo)
Oral corticosteroids	3	2	1	2	0	16 d
Antihistamines	1	N/A	1	0	0	N/A
Oral antibiotics	2	3	2	0	0	3
Anti-TNF <sup>d</sup>	3	10 (7–29)	0	3	0	7 (2–10)
Dapsone	1	6	0	1	0	3

Treatment duration and time to response were calculated on the basis of those with data available.

anti-TNF, anti-tumor necrosis factor; CR, complete response; N/A, not applicable; NR, no response; PR, partial response.

a No response was defined by the terms no response, recurrence, poor, weak, worsened, and/or no change.

b Partial response was defined by the terms favorable response, responding, decreased swelling, controlled, improved, much improved, greatly improved, and/or markedly better.

c Complete response was defined by the terms improved completely, no ongoing symptoms, not active, controlled with no recurrence, cleared, asymptomatic, resolved, largely resolved, complete control, clinical remission, and/or normal.

d All 3 patients who received anti-TNF therapy received infliximab.

## DISCLOSURES

**Author contributions:** SA Urquhart: literature search, data collection and interpretation, formation of figures and tables, and drafting of manuscript. GY Kim: data analysis and interpretation, and critical review of manuscript. KR Anderson: data analysis and interpretation, and critical review of manuscript. VG Chedid: literature search, study design, data interpretation, and critical review of manuscript, and is the article guarantor.

**Financial disclosure:** None to report.

**Previous presentation:** This study was presented at the Advances in Inflammatory Bowel Disease conference; December 14, 2023; Orlando, Florida.

**Informed consent** could not be obtained for this case report.

Received September 9, 2024; Accepted October 17, 2024

## REFERENCES

- Rogler G, Singh A, Kavanaugh A, Rubin DT. Extraintestinal manifestations of inflammatory bowel disease: Current concepts, treatment, and implications for disease management. *Gastroenterology*. 2021;161(4):1118–32.
- Farhi D, Cosnes J, Zizi N, et al. Significance of erythema nodosum and pyoderma gangrenosum in inflammatory bowel diseases: A cohort study of 2402 patients. *Medicine (Baltimore)*. 2008;87(5):281–93.
- Ribaldone DG, Brigo S, Mangia M, Saracco GM, Astegiano M, Pellicano R. Oral manifestations of inflammatory bowel disease and the role of non-invasive surrogate markers of disease activity. *Medicines (Basel)*. 2020;7(6):33.
- Muhvić-Urek M, Tomac-Stojmenović M, Mijandrušić-Sinčić B. Oral pathology in inflammatory bowel disease. *World J Gastroenterol*. 2016;22(25):5655–67.
- Lauritano D, Boccalari E, Di Stasio D, et al. Prevalence of oral lesions and correlation with intestinal symptoms of inflammatory bowel disease: A systematic review. *Diagnostics (Basel)*. 2019;9(3):77.
- Bogenrieder T, Rogler G, Vogt T, Landthaler M, Stolz W. Orofacial granulomatosis as the initial presentation of Crohn's disease in an adolescent. *Dermatology*. 2003;206(3):273–8.
- Girlich C, Bogenrieder T, Palitzsch KD, Schölmerich J, Lock G. Orofacial granulomatosis as initial manifestation of Crohn's disease: A report of two cases. *Eur J Gastroenterol Hepatol*. 2002;14(8):873–6.
- McCorkle CE, Seethala RR, Gillman GS. An uncommon case of lip swelling: Granulomatous cheilitis associated with Crohn's disease. *Am J Otolaryngol*. 2021;42(2):102897.
- Durgin JS, Rodriguez O, Sollecito T, et al. Diagnosis, clinical features, and management of patients with granulomatous cheilitis. *JAMA Dermatol*. 2021;157(1):112–4.
- Gavioli CFB, Florezi GP, Dabronzo MLD, Jiménez MR, Nico MMS, Lourenço SV. Orofacial granulomatosis and Crohn disease: Coincidence or pattern? A systematic review. *Dermatology*. 2021;237(4):635–40.
- Lazzerini M, Bramuzzo M, Ventura A. Association between orofacial granulomatosis and Crohn's disease in children: Systematic review. *World J Gastroenterol*. 2014;20(23):7497–504.
- Malmquist M, Rabe H, Malmborg P, et al. Frequent occurrence of perianal disease and granuloma formation in patients with Crohn's disease and coexistent orofacial granulomatosis. *Dig Dis Sci*. 2023;68(7):3129–38.
- Phillips F, Verstockt B, Sladek M, et al. Orofacial granulomatosis associated with Crohn's disease: A multicentre case series. *J Crohns Colitis*. 2022;16(3):430–5.
- Freysdóttir J, Zhang S, Tilakaratne WM, Fortune F. Oral biopsies from patients with orofacial granulomatosis with histology resembling Crohn's disease have a prominent Th1 environment. *Inflamm Bowel Dis*. 2007;13(4):439–45.
- Mentzer A, Nayee S, Omar Y, et al. Genetic association analysis reveals differences in the contribution of NOD2 variants to the clinical phenotypes of orofacial granulomatosis. *Inflamm Bowel Dis*. 2016;22(7):1552–8.
- Seghers AK, Grosber M, Urbain D, Mana F. Cheilitis granulomatosa and Crohn's disease: A case report. *Acta Gastroenterol Belg*. 2019;82(2):326–8.
- Taxonera C, Alba C, Colmenares M, Olivares D, Rey E. Recurrent granulomatous cheilitis associated with Crohn's disease successfully treated with ustekinumab: Case report and literature review. *Therap Adv Gastroenterol*. 2020;13:1756284820934327.
- Stoevesandt J, Keita DU, Goebeler M. Disease-related burden and long-term outcome in orofacial granulomatosis: Observations from a large single-centre cohort. *Clin Exp Dermatol*. 2022;47(6):1169–73.
- Mignogna MD, Fedele S, Lo Russo L, Adamo D, Satriano RA. Effectiveness of small-volume, intralesional, delayed-release triamcinolone injections in orofacial granulomatosis: A pilot study. *J Am Acad Dermatol*. 2004;51(2):265–8.
- Fedele S, Fung PP, Bamashmous N, Petrie A, Porter S. Long-term effectiveness of intralesional triamcinolone acetonide therapy in orofacial

- granulomatosis: An observational cohort study. *Br J Dermatol* 2014;170(4):794–801.
21. Lichtenstein GR, Loftus EV, Isaacs KL, Regueiro MD, Gerson LB, Sands BE. ACG clinical guideline: Management of Crohn's disease in adults [published correction appears in *Am J Gastroenterol*. 2018;113(7):1101]. *Am J Gastroenterol*. 2018;113(4):481–517.
  22. Mentzer A, Goel R, Elliott T, et al. Azathioprine is effective for oral involvement in Crohn's disease but not for orofacial granulomatosis alone. *J Oral Pathol Med*. 2016;45(4):312–8.
  23. O'Neill ID, Scully C. Biologics in oral medicine: Oral Crohn's disease and orofacial granulomatosis. *Oral Dis*. 2012;18(7):633–8.
  24. Elliott T, Campbell H, Escudier M, et al. Experience with anti-TNF- $\alpha$  therapy for orofacial granulomatosis. *J Oral Pathol Med*. 2011;40(1):14–9.
  25. Feuerstein JD, Ho EY, Shmidt E, et al. AGA clinical practice guidelines on the medical management of moderate to severe luminal and perianal fistulizing Crohn's disease. *Gastroenterology*. 2021;160(7):2496–508.

---

**Copyright:** © 2024 The Author(s). Published by Wolters Kluwer Health, Inc. on behalf of The American College of Gastroenterology. This is an open access article distributed under the terms of the Creative Commons Attribution-Non Commercial-No Derivatives License 4.0 (CCBY-NC-ND), where it is permissible to download and share the work provided it is properly cited. The work cannot be changed in any way or used commercially without permission from the journal.